The Prostate 17:31–40 (1990)

Species- and Organ-Specificity of Secretory Proteins Derived From Human Prostate and Seminal Vesicles

G. Aumüller, J. Seitz, H. Lilja, P.-A. Abrahamsson, H. von der Kammer, and K.-H. Scheit

Department of Anatomy and Cell Biology, University of Marburg, Marburg (G.A., J.S.), and Max-Planck-Institut für Biophysikal Chemie, Göttingen (H.v.d.K., K.-H.S.), Federal Republic of Germany; Departments of Clinical Chemistry (H.L.) and Urology (P.-A.A.), University of Lund, Malmö General Hospital, Malmö, Sweden

Polyclonal antibodies against semenogelin (SG) isolated from human seminal vesicle secretion and acid phosphatase (PAP), β-microseminoprotein (β-MSP), and Prostate-Specific Antigen (PSA) derived from human prostatic fluid, as well as a monoclonal antibody against β-MSP were used for immunocytochemical detection of the respective antigens in different organs from different species. SG immunoreactivity was detected in the epithelium of the pubertal and adult human and in monkey seminal vesicle, ampulla of the vas deferens, and ejaculatory duct. PAP, β-MSP, and PSA immunoreactivities were detected in the pubertal and adult human prostate and the cranial and caudal monkey prostate. With the exception of a weak PSA immunoreactivity in the proximal portions of the ejaculatory duct, none of the latter antisera reacted with seminal vesicle, ampullary, and ejaculatory duct epithelium. Among the non-primate species studied (dog, bull, rat, guinea pig) only the canine prostatic epithelium displayed a definite immunoreactivity with the PAP antibody and a moderate reaction with the PSA antibody. No immunoreaction was seen in bull and rat seminal vesicle and canine ampulla of the vas deferens with the SG antibody. The same was true for the (ventral) prostate of rat, bull, and dog for β-MSP. The epithelium of the rat dorsal prostate showed a slight cross-reactivity with the monoclonal antibody against β-MSP and one polyclonal antibody against PSA. The findings indicate a rather strict species-dependent expression of human seminal proteins which show some similarities in primates, but only marginal relationship to species with different physiology of seminal fluid.

Key words: immunocytochemistry, ejaculatory ducts, ampulla of vas deferens, primates, carnivores, rodents

INTRODUCTION

Human seminal fluid is known to contain a great variety of secretory proteins which exert different biochemical functions such as semen coagulation and liquefaction and regulation of calcium fluxes and immunological mechanisms (for review, see [1]). The search in forensic medicine for specific markers of human semen left during

Received for publication December 8, 1989; accepted March 8, 1990.

Address reprint requests to Gerhard Aumüller, Department of Anatomy and Cell Biology, Robert-Koch-Str. 6, D-3550 Marburg, Federal Republic of Germany.

sexual assault has revealed a variety of different proteins [2,3], one of which eventually turned out to be the essential gel-forming substance delivered from seminal vesicles into semen (semenogelin: see [4]; MHS-5: see [5]). Although quite a number of secretory proteins are known in the human prostate, only three [6] have gained major importance as diagnostic tools [7], namely acid phosphatase ("PAP"), prostate-specific antigen ("PSA", [8]), and β-microseminoprotein ("β-MSP", [9,10]). In different mammalian species, the male accessory sex glands vary considerably with respect to their morphology and function, obviously depending on the species-specific requirements of their functions secondary to differences in the environments and sexual habits.

We have used monospecific antisera against the four human seminal proteins mentioned (PAP, PSA, β-MSP, SG) i) to monitor their expression during postnatal development in the respective human glands, ii) to compare the immunological relationship of these proteins in glands from different species, and iii) to scrutinize the comparability of immunohistochemical results achieved with different antisera preparations.

Immunoreactivity of the proteins was detected in the respective glands only after onset of puberty and there was a close relationship in the immunoreactivities of the human and monkey prostate and seminal vesicle, respectively. Depending on the antiserum preparation used, there was a cross-reaction with human prostate secretory proteins in canine and rat prostate. The results indicate a relatively high level of species specificity of the proteins and their respective secretion sites.

MATERIALS AND METHODS

Tissue

Paraffin blocks of Bouin-fixed tissues were retrieved from files of the Department of Anatomy. They included infantile (5 years), pubertal (15 years), and adult (19 years) human seminal vesicle and prostate, monkey *(Macaca mulatta)* prostate and seminal vesicle, bull, rat, and guinea pig prostate and seminal vesicle as well as canine prostate and ampulla of the vas deferens. The tissues had been used in previous studies [11–14]. In addition, the following human autopsy specimens (Bouin-fixed, paraffin-embedded) were used: brain, tongue, pituitary, lung, kidney, liver, stomach, epididymis, and testis. Sections were cut at 5 μm thickness from these blocks and were stained with hematoxylin and eosin for morphological examination. A sequence of six sections was used for immunoreactions. The unlabeled antibody-enzyme method was applied to detect the immunoreaction [15] in the case of polyclonal primary antibodies. With monoclonal primary antibodies, the indirect immunoperoxidase method was applied. Controls included omission of the primary (specific) antibody to establish the specificity of the staining. In addition to paraffin sections of human prostate, Epon-embedded material fixed in 0.1% glutaraldehyde in 0.1 M sodium cacodylate buffer pH 7.3 was used. Semithin sections were serially cut at 1 μm thickness and used for serial staining. Immunoreaction was detected by the indirect immunofluorescence method. To check the influence of fixation and embedding, cryostat sections of human prostate were processed for immunofluorescence. No differences in the immunoreactivity of cryostat and paraffin section were observed.

Antisera

A highly specific polyclonal antiserum against type 2a acid phosphatase from human seminal fluid, earlier described [12], was used. Affinity-purified antibodies against PSA I (10.3 mg/ml) and β-MSP [11 mg/ml] have been earlier described [6]. A monoclonal antibody against β-MSP was prepared according to [16]. The polyclonal antibody against the basic semenogelin fragment (6.2 mg/ml) has already been described [17]. A polyclonal antibody against a highly purified preparation of PSA was raised in rabbits by injecting the 33 kD band of SDS-PAGE at this preparation into the back skin of a rabbit. Booster injections were repeated 4 and 6 weeks later. As with the antibodies mentioned, also this antibody (PSA II) was characterized by Western blotting and stained only a single band of seminal proteins. It was used at a dilution of 1:100.

RESULTS

Antibody Specificity

A survey of the immunoreactions in the male accessory sex glands achieved with the different antibodies used is given in Table I. Since the monoclonal antibody against β-MSP and the polyclonal antibody against PSA (II) had to be characterized in more detail, their organ specificity was monitored. With the exception of a slight non-specific background staining of the squamous epithelium of tongue in the case of the β-MSP-mab, no immunoreaction was observed with both antibodies in all organs tested other than prostate.

SG Immunoreactivity

A positive immunoreaction was seen in the epithelium of the ampulla of the vas deferens, the seminal vesicle (Fig. 1), and the adluminal portions of the ejaculatory duct (Fig. 2). It was absent from the immature seminal vesicle epithelium of 5 year-old child (Fig. 3). While in bovine, rat, and guinea pig seminal vesicle and the ampulla of the canine vas deferens (Fig. 6) no immunoreaction was seen, it was strong in the monkey seminal vesicle (Fig. 4) and even more pronounced in the ejaculatory duct epithelium (Fig. 5) of the monkey.

PSA Immunoreactivity

Serial semithin sections sequentially stained for PAP (Fig. 8), PSA-I (Fig. 7), and β-MSP (Fig. 9) showed the coincidence of the immunoreactions. It was slightly more generalized in the case of PSA (Fig. 7) compared to the very differential reactions of PAP and β-MSP. In the juvenile prostate of a 15 year-old boy (Fig. 10) the immunoreaction was clearly polarized with a very pronounced apical immunoreaction seen at higher magnification (Fig. 11). With PSA-antibody I, a generalized moderate immunoreaction was observed even in the prostatic epithelium of the 5 year-old boy (Fig. 12). When PSA-antibody II was used, no immunoreaction was observed.

PSA-antibodies I and II reacted positively with the monkey prostatic epithelium (cranial portions, Fig. 15), but only PSA-antibody I showed a positive reaction with canine prostatic epithelium (Figs. 13, 14). Squamous metaplastic cells present in the

TABLE I. Immunohistochemical Results*

Organs	Antibodies: Semenogelin (SG) polyclonal, rabbit	Acid phosphatase (PAP) polyclonal, rabbit	Prostate-specific antigen I (PSA) polyclonal, rabbit	Prostate-specific antigen II (PSA) polyclonal, rabbit	β-microseminoprotein I (β-MSP) polyclonal, rabbit	β-microseminoprotein II (β-MSP) monoclonal, mouse
Human prostate						
Infantile	0	0	(+)	0	0	0
Pubertal	0	+	+	+	0–+	+
Adult	0	+–++	+–++	+	(+)–++	++
Seminal vesicle						
Infantile	0	0	0–(+)	0	0	0
Pubertal	(+)	0	0	0	0	0
Adult	+–++	0	0	0	0	0
Ampulla duct. deferentis	+–++	0	0	0	0	0
Ejaculatory duct	(+)–+	0–(+)	0–(+)	0	0	0
Monkey prostate						
Cranial	0	+	(+)	(+)	(+)–+	++
Caudal	0	+	0	0	+	(+)
Seminal vesicle	+	0	0	0	0	0
Ejaculatory duct	++	0	0	0	0	0
Dog prostate	0	+	(+)–+	0	0	0
Ampulla ductus deferentis	0	0	0	0	0	0
Bull prostate	0	0	0	0	0	0
Seminal vesicle	0	0	0	0	0	0
Rat, guinea pig prostate (ventral)	0	0	0	0	0	0
				Rat dorsal prostate +		Rat dorsal prostate +
Seminal vesicle	0	0	0	0	0	0

*Symbols (intensity of immunoreaction): 0 negative; (+) weak; + positive; ++ strong.

canine prostate shown in Figure 14 were due to hormonal treatment (see [13], group IV); they were not immunoreactive.

β-MSP Immunoreactivity

The immunoreactivities achieved with both β-MSP antibodies were essentially identical with a slightly stronger reaction in the case of the monoclonal antibody. The epithelium of the adult prostate (Fig. 16) showed a moderate to strong immunoreaction and the infantile prostatic epithelium (Fig. 17) was clearly unstained. A very interesting staining pattern was observed in the monkey prostate, where (preferentially in the cranial lobe, Fig. 18) individual cells were most intensely labeled while others were in the background range. A similar staining pattern was seen with the PAP antibody (not shown). Neither the canine and bovine nor the rodent (ventral) prostate epithelium reacted with β-MSP antibodies. Interestingly, the rat dorsal prostate showed a distinct immunoreaction with PSA-antibody II and the monoclonal antibody against β-MSP.

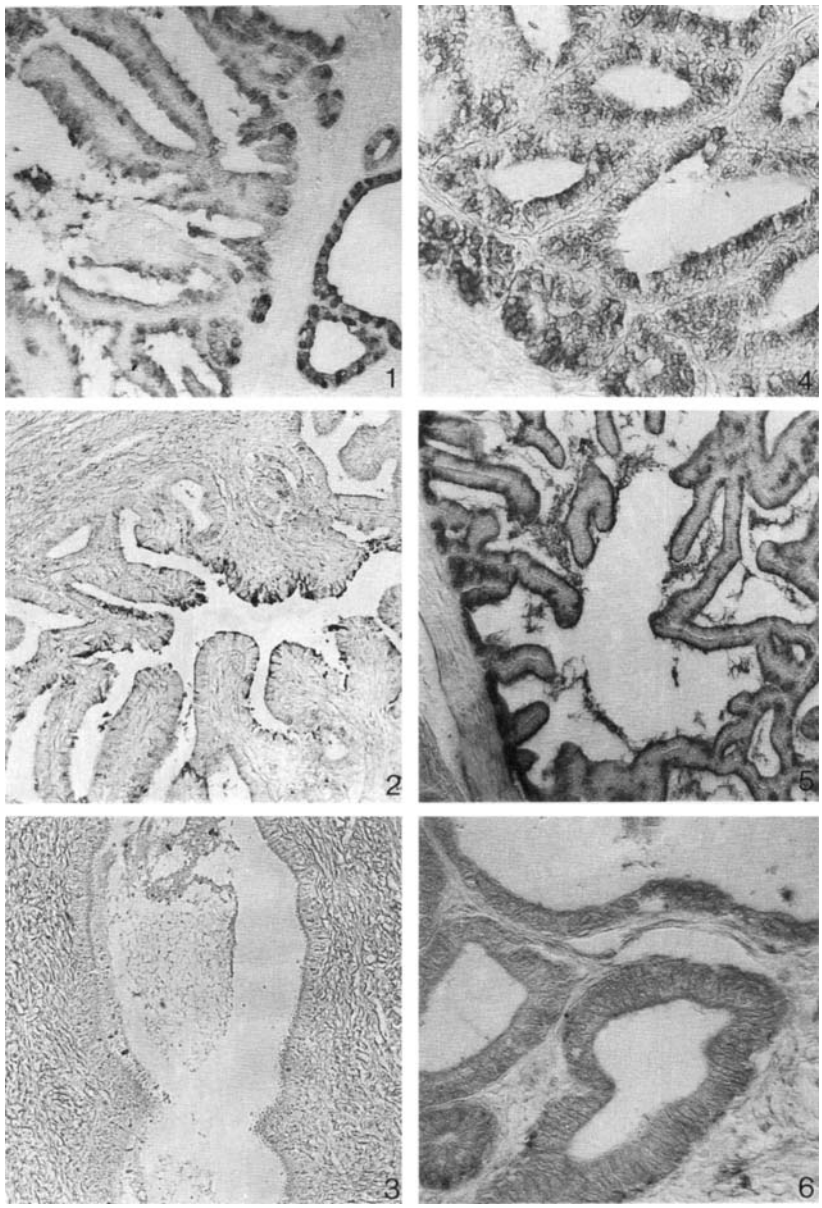

Fig. 1. Human seminal vesicle epithelium shows a moderate or strong immunoreaction for semenogelin. The deeper glandular portions are usually more immunoreactive than the adluminal portions. ×40.

Fig. 2. Ejaculatory duct from a 17 year-old boy. Single adluminal epithelial cells display semenogelin immunoreactivity. The deeper gland-like structures are usually non-reactive. ×40.

Fig. 3. Seminal vesicle of the newborn. No immunoreactivity for semenogelin is present. ×40.

Fig. 4. The seminal vesicle epithelium in the monkey shows a moderate cross-immunoreactivity with an antibody directed against human semenogelin. ×40.

Fig. 5. Ampulla of the vas deferens in the rhesus monkey. The epithelium shows a strong semenogelin immunoreactivity. ×40.

Fig. 6. Ampulla of the canine vas deferens. There is only a non-specific background reaction with the semenogelin antibody. ×100.

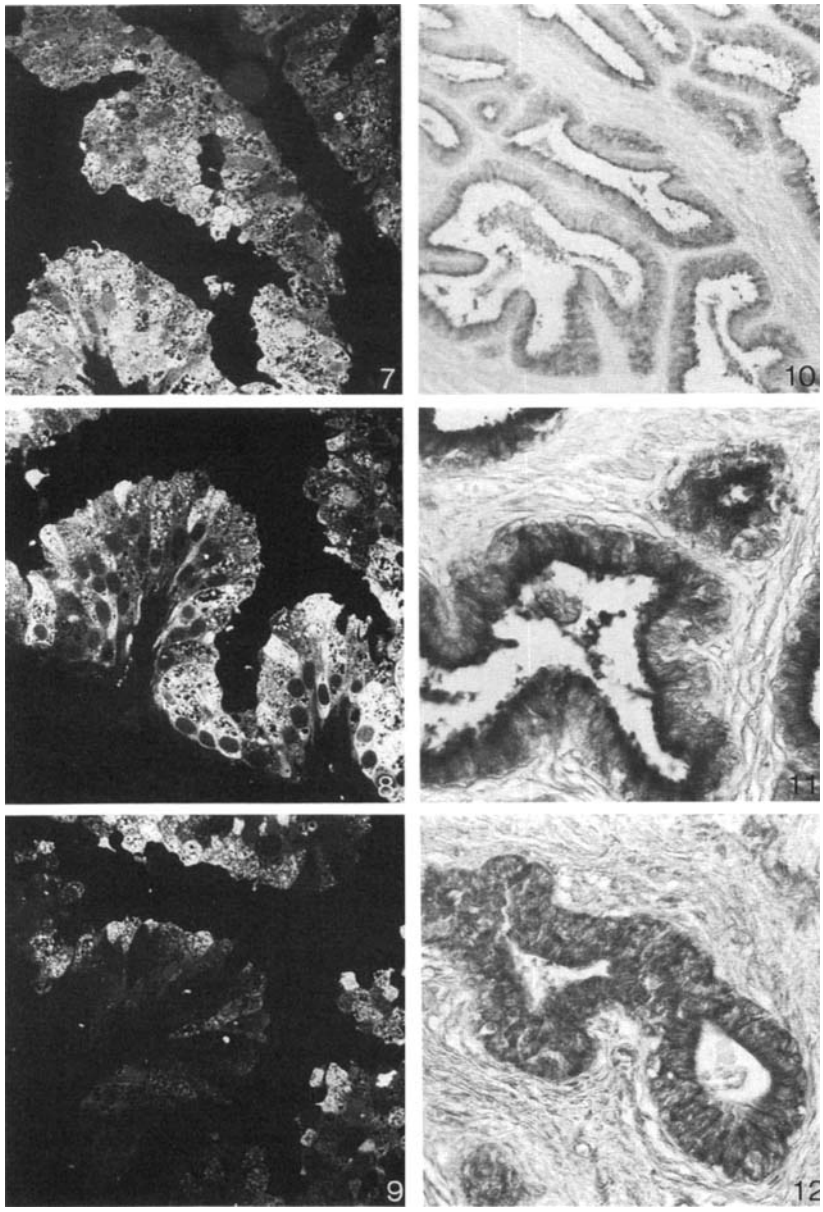

Fig. 7. PSA immunofluorescence on a semithin section of human prostate. × 150.

Fig. 8. Prostatic acid phosphatase immunoreaction in a section subsequent to Figure 7. Immunoreactivity is less generalized and pronounced in the intracellular secretion granules. × 150.

Fig. 9. β-MSP immunofluorescence in a section cut adjacent to that in Figure 8. Comparable intensity and distribution of immunofluorescence are seen in both sections. × 150.

Fig. 10. PSA immunoreactivity in the prostate of a 15 year-old boy. Moderate reaction of the apical portion of the cells. × 40.

Fig. 11. At higher magnification, the prevalent staining of the apical portion of the epithelium is easily noticed. × 75.

Fig. 12. Positive generalized immunoreaction of prostatic epithelium of a 5 year-old boy with a PSA-antibody. × 75.

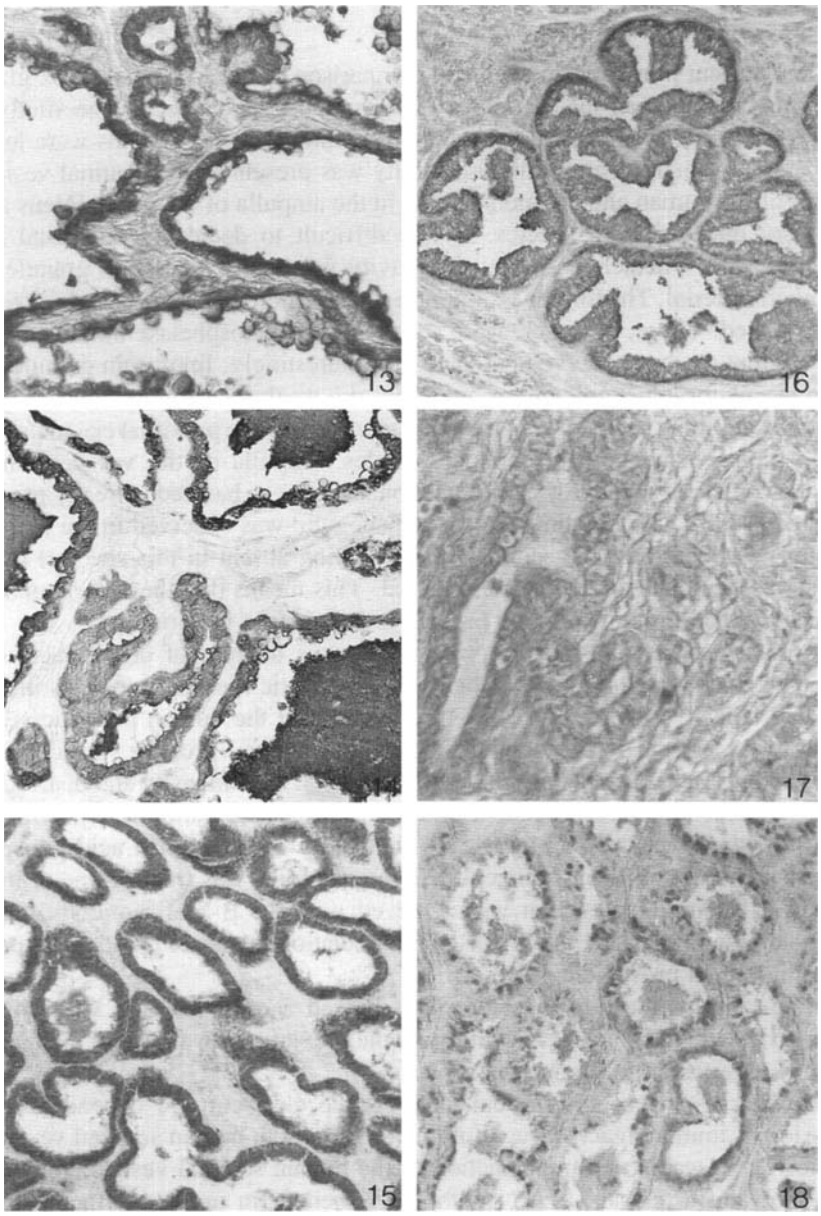

Fig. 13. PSA (antibody I) immunoreactivity in the prostate of a 12 year-old dog. Acini are dilated and immunoreactive epithelium is low. ×75.

Fig. 14. Prostate from a castrated dog treated for 6 months with androstanediol, estradiol, and tamoxifen (for details see [13]). Strong immunoreaction of most epithelial cells. ×75.

Fig. 15. PSA immunoreactivity in the cranial lobe of the monkey prostate. Homogeneous reaction of the epithelium. ×40.

Fig. 16. Immunoreactivity of β-MSP in the prostate of a 19 year-old man is moderate ×75.

Fig. 17. In a 5 year-old boy prostatic epithelium shows no immunoreaction with the β-MSP antibody. ×75.

Fig. 18. A very heterogeneous immunoreactivity is seen in the cranial lobe of a monkey prostate with the β-MSP antibody. Cells displaying a positive immunoreaction are interspersed between non-reactive cells. ×40.

DISCUSSION

The present immunohistochemical comparison of male accessory sex glands in six different mammalian species shows a very high degree of species-specificity in the seminal-vesicle-derived protein semenogelin, while prostatic proteins were less species-specific. Semenogelin immunoreactivity was present in the seminal vesicle epithelium of the human and the monkey and in the ampulla of the vas deferens and the ejaculatory ducts of both species. It was difficult to decide in the distal human ejaculatory duct whether the immunoreactivity was due to secretion granules or to reabsorbed material. The former assumption appears more likely, as no side differences were observed. These, however, were seen with acid phosphatase immunoreactivity in the ejaculatory duct observed on one case. Interestingly, lipofuscin granules abundant in ejaculatory duct epithelium often reveal a weak PSA immunoreactivity. This would indicate some backflow of prostatic secretion into the proximal ejaculatory duct.

In monkey and human, seminal vesicles, ampulla of the vas deferens, and ejaculatory duct obviously form one functional entity, as has been already previously suggested [18,19]. No immunoreactive semenogelin was observed in the ampulla of the canine vas deferens (the seminal vesicles being absent in this species) or in the seminal vesicles of the other species studied. This means that the semenogelin-PSA system described in human [20,21] seems to be specific for primates.

Contrary to seminal vesicle proteins, various degrees of cross-reactivities in different species were observed in the case of prostatic secretory proteins indicating a less specialized situation in this urethral gland. All the human prostatic secretory proteins were present in the cranial lobe of the monkey prostate (the caudal lobe displaying only acid phosphatase immunoreactivity). The intensity and distribution of the immunoreaction were dependent on the antibody preparation. As previously reported [13] there was also a strong cross-reactivity of the human acid phosphatase antibody with the canine prostatic epithelium. The same was true for one of the PSA antibodies. No immunoreaction was achieved with the β-MSP antibody in canine prostatic epithelium. There is obviously a dissociation in canine prostate of functions present in human prostatic epithelium.

Interestingly, the dorsal rat prostate showed a cross-reaction with antiserum against PSA and β-MSP. This is contrary to the previous view [22] that the rat ventral prostate is equivalent to the human prostate.

Another aspect of the present study is the clear-cut age dependence in the expression of immunoreactive secretory material in both human seminal vesicles and prostate. There was no immunoreaction of the human seminal vesicle epithelium of a newborn and a 5 year-old boy with the semenogelin antibody. In the infantile prostate, a diffuse immunoreaction of the epithelium was observed only with one PSA-antibody (I). This confirms reports of Wernert and Dhom [23] who observed PSA immunoreactivity in prostatic epithelium of a newborn. Since only one of both PSA antibodies reacted with immature prostatic epithelium, this may be due to the epitope-specificity of the antiserum. In a previous study [12], we used antibodies against secretory (ac P2, [24]) and tissue-type (ac P4) prostatic acid phosphatase and found a positive immunoreaction of prepubertal prostatic epithelium only with the latter. We therefore presume a certain molecular heterogeneity of PSA resulting in different antisera (compare [25]) which recognize either the mature secretory protein or a related non-secretory precursor. It is likely that one of the antisera (PSA antibody

II) may recognize only PSA, whereas the other antibody (PSA antibody I) may recognize both PSA *and* the translation product. Another explanation would be that postnatally elevated testosterone levels would intermittingly stimulate some immature prostatic cells to produce secretory proteins. A comparable situation is known from the female prostate [26,27]. During puberty the expression of semenogelin immunoreactivity in the seminal vesicles and of PSA, acid phosphatase, and β-MSP immunoreactivities in the prostate develops rather simultaneously. In the prostate, no clear-cut progress in developing immunoreactivity from proximal (close to the urethra) to distal (underneath the capsule) is observed; rather, the diameter of the developing acini appears to be relevant for the onset of functional maturation.

Taking together our findings, they indicate an androgen-dependent pattern of functional (i.e., secretory) maturation of the epithelia of the human male accessory sex glands and a coordinated temporal appearance of secretion. The qualitative differences of the secretory proteins between various species are very pronounced in the case of the seminal vesicle; they appear a little less decisive in the case of the prostate.

ACKNOWLEDGMENTS

The authors gratefully acknowledge the technical help of Michael Dreher and Irmgard Dammshäuser. Thanks are due to Mrs. Anita Jeske for typing the manuscript. The financial support of the Deutsche Forschungsgemeinschaft (Se 370/2-6) is gratefully acknowledged.

REFERENCES

1. Aumüller G, Seitz J: Protein secretion and secretory processes in male accessory sex glands. Int Rev Cytol 121:127–231, 1990.
2. Graves HC, Sensabaugh GF, Blake ET: Postcoital detection of a male-specific semen protein. Application to the investigation of rape. N Engl J Med 312:338–343, 1985.
3. Akiyama K, Nakamura T, Iwanaga S, Hara M: On the chymotrypsin-like activity of prostate specific antigen, gamma-seminoprotein (gamma-Sm). Nippon Hoigaku Zasshi 42:154–160, 1988.
4. Lilja H, Abrahamsson P-A, Lundwall A: Semenogelin, the predominant protein in human semen. J Biol Chem 264:1894–1900, 1989.
5. Herr JC, Spell DR, Conklin DJ, Flickinger CJ: Electron microscopic immunolocalization of seminal vesicle-specific antigen in human seminal vesicle. Biol Reprod 40:333–342, 1989.
6. Lilja H, Abrahamsson P-A: Three predominant proteins secreted by the human prostate gland. The Prostate 12:29–38, 1988.
7. Abrahamsson P-A, Lilja H, Falkmer S, Wadström LB: Immunohistochemical distribution of the three predominant secretory proteins in the parenchyma of hyperplastic and neoplastic prostate glands. The Prostate 12:39–46, 1988.
8. Wang MC, Valenzuela LA, Murphy GP, Chu TM: Purification of a human prostate specific antigen. Invest Urol 17:159–163, 1979.
9. Akiyama K, Yoshioka Y, Schmid K, Offner GD, Troxler RF, Tsuda R, Hara M: The amino acid sequence of human β-microseminoprotein. Biochim Biophys Acta 829:288–294, 1985.
10. Dubé JY, Pelletier G, Gagnon P, Tremblay RR: Immunohistochemical localization of a prostatic secretory protein of 94 amino acids in normal prostatic tissue in primary prostatic tumors and in their metastases. J Urol 138:883–887, 1987.
11. Aumüller G: Fine structure of monkey (*Macaca mulatta*) male accessory sex glands, juvenile and adult. Z Mikrosk Anat Forsch 90:545–556, 1976.
12. Aumüller G, Seitz J, Bischof W: Immunohistochemical study on the initiation of acid phosphatase secretion in the human prostate. J Androl 4:183–191, 1983.

13. Aumüller G, Vedder H, Enderle-Schmitt U, Seitz J: Immunohistochemistry of canine acid phosphatase. The Prostate 11:1–15, 1987.
14. Aumüller G, Enderle-Schmitt U, Seitz J, Müntzing J, Chandler JA: Ultrastructure and immunohistochemistry of the lateral prostate in aged rats. The Prostate 10:245–256, 1987.
15. Sternberger LA, Hardy PH, Cuculis JJ, Meyer HG: The unlabeled antibody-enzyme method of immunohistochemistry. J Histochem Cytochem 18:315–333, 1970.
16. von der Kammer H, Krauhs E, Aumüller G, Scheit KH: Characterization of a monoclonal antibody specific for prostatic secretory protein of 94 amino acids (PSP 94) and development of a two-site binding enzyme immunoassay for PSP 94. Clin Chim Acta (in press).
17. Lilja H, Jeppsson J-O: Aminoacid sequence of the predominant basic protein in human seminal plasma. FEBS Lett 182:181–184, 1985.
18. Aumüller G, Brühl B: Über den Bau der Ampulla ductus deferentis des Menschen. Verh Anat Ges 71:561–564, 1977.
19. Riva A, Testa-Riva F, Usai E, Cossu M: The ampulla ductus deferentis in man, as viewed by SEM and TEM. Arch Androl 8:157–164, 1982.
20. Lilja H, Laurell C-B: Liquefaction of coagulated human semen. Scand J Clin Lab Invest 44:447–452, 1984.
21. Lilja H: A kallikrein-like serine protease in prostatic fluid cleaves the predominant seminal vesicle protein. J Clin Invest 76:1899–1902, 1985.
22. Price D: Comparative aspects of development and structure in the prostate. Natl Cancer Inst Mongr 12:1–27, 1963.
23. Wernert N, Dhom G: Immunohistochemistry of the prostate and diverse prostate carcinomas. In Aumüller G, Krieg M, Senge Th (eds): "New Aspects in the Regulation of Prostatic Function." Munich: W. Zuckschwerdt, 1989, pp 69–81.
24. Lam K-W, Li C-Y, Yam LT, Sun T, Lee G, Ziesmer S: Improved immunohistochemical detection of prostatic acid phosphatase by a monoclonal antibody. The Prostate 15:13–21, 1989.
25. Dubé JY, Gandreault D, Tremblay RR: The concentration of immunoreactive prostate specific antigen is not decreased in viscous semen samples. Andrologia 21:136–139, 1989.
26. Pollen JJ, Dreilinger A: Immunohistochemical identification of prostatic acid phosphatase and prostate specific antigen in female periurethral glands. Urology 23:303–304, 1984.
27. Tepper SL, Jagirdar J, Heath D, Geller SA: Homology between the female paraurethral (Skene's) glands and the prostate. Lab Med 108:423–425, 1984.